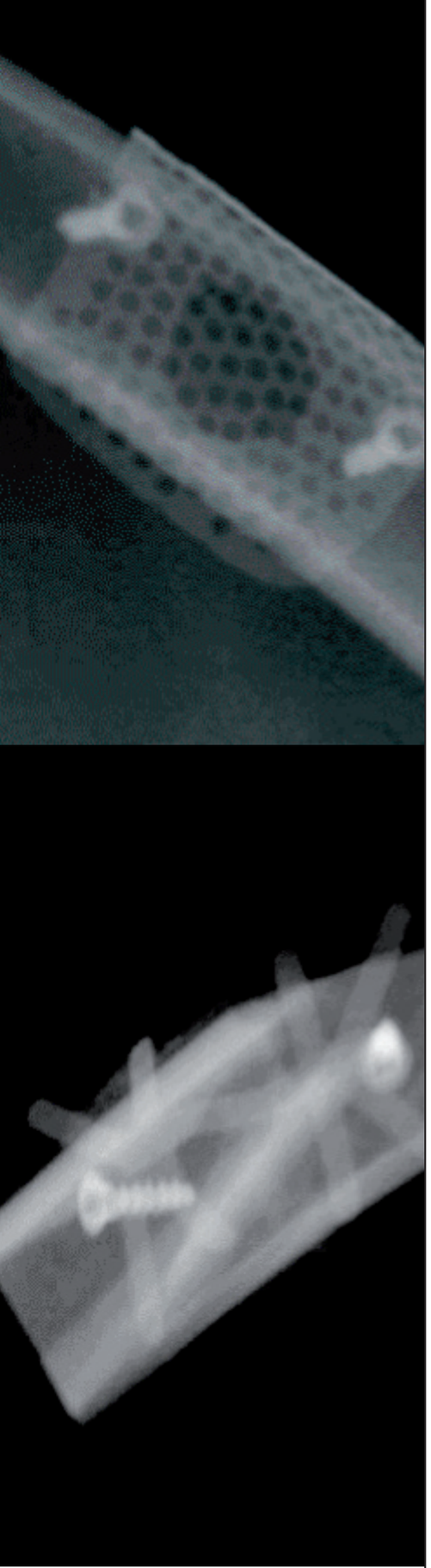

Riference **OP-BI0703001P1**

Publication date and location

March 8-10, 2007
San Antonio TEXAS

Event

2007 AO Annual Meeting

Headline scientific research

Bone regeneration in femur defects in rabbits treated with an e-PTFE and VBR titanium membrane

Authors

Lorenzo Ravera*, Antonio Scarano**, Giovanna Iezzi**, Fabrizio Morelli*, adriano Piattelli**

(*Private Practice, Torino, Italy, **Dental School, University of Chieti-Pescara, Italy)

Index

ORALPLANT SUISSE SA
Division Implantology
Via Penate 16
CH-6850 Mendrisio

T +41 (0) 91 971 54 00
info@oralplant.ch

www.oralplant.com

#28

Bone regeneration in femur defects in rabbits treated with an e-PTFE and a VBR titanium membrane

Lorenzo Ravera *, Antonio Scarano**, Giovanna Iezzi **, Fabrizio Morelli *, Adriano Piattelli**
(* Private Practice, Torino, Italy; ** Dental School, University of Chieti-Pescara, Italy)

2007 AO ANNUAL MEETING
San Antonio
TEXAS
March 8-10,2007

ABSTRACT

The aim of this work was an histological study of the bone healing of femoral defects in rabbits treated with an e-PTFE titanium reinforced membrane (W. L. Gore & Associates, Flagstaff, AZ, USA) and a new titanium membrane (VBR - Valve Bone Regeneration, Oralplant, Cordenons, Italy). Twelve New Zealand rabbits, weighing about 2.5 Kg were used in this study. One defect (6 mm x 6 mm) was created in each femur. Twelve defects were covered with e-PTFE membranes (control defects) and the other 12 defects were covered with the titanium membrane (test defects). The rabbits were killed after 8 weeks, with an intravenous injection of Tanax, and the block sections, containing the bone defects, were retrieved. A total of 24 defects were retrieved and the specimens were processed to obtain thin ground sections. All the defects of both groups were completely filled by mature, lamellar bone. Newly formed bone was in close, direct contact with both membranes and no gaps were present. Both membranes adhered closely to the bone defects. The e-PTFE membrane appeared to be compressed, in a few areas, by the overlying soft tissues. No inflammatory cell infiltrate was present. No multinucleated giant cells were present. No differences were found in the quantity of the bone regeneration using these two types of membranes, and both membranes have shown a high degree of biocompatibility, and did not induce any untoward effects.

INTRODUCTION

The need to insert dental implants with a guided prosthetic axis in patients with atrophy of the jawbones, has determined the use of numerous techniques of guided bone regeneration.

The guided bone regeneration is based on the use of a membrane that, acting as a mechanical semi-waterproof barrier, excludes the connective and epithelial cells from the surgical repair site and, at the same time, favours the osteopromoting cells invasion.

The fundamental conditions to obtain the bone regeneration are:

-highest contact surface between the surrounding bone and the blood clot

- highest blood clot stability (space making effect)

- minimal damage to the overlying soft tissues.

In bone defects with low space making capability (open defects) the membrane, as well as creating a protective and semi-waterproof compartment for the blood clot keeps the space (space making effect) favoring the bone regeneration.

AIM

The aim of this work was: 1) an histological study of the bone healing of femoral defects in rabbits treated with an e-PTFE reinforced titanium membrane (W.L. Gore & Associates, Flagstaff, AZ, USA) and a new VBR titanium membrane (Valve Bone Regeneration, Oralplant, Cordenons, Italy); 2) an evaluation of the space making capability of both membranes.

MATERIAL AND METHODS

Twelve New Zealand rabbits, weighing about 2,5 Kg, were used.

One defect (6mm x 6mm) was created in each femur.

Twelve defects were covered with e-PTFE membranes (control defects)

Twelve defects were covered with VBR titanium membranes (test defects).

The rabbits were killed after 8 weeks and the block sections, containing the bone defects, were retrieved.

A total of 24 defects were retrieved and the specimens were processed to obtain thin ground sections.

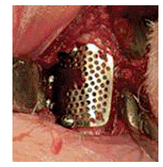

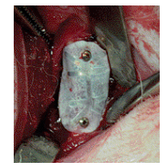

SURGICAL PROCEDURE

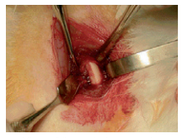

View of the anterior-superior femur surface

Bone defect

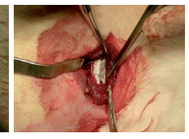

e-PTFE membrane placed and fixed with two screws

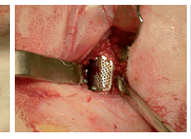

VBR titanium membrane placed and fixed with two screws



e-PTFE membrane x ray covering the defect

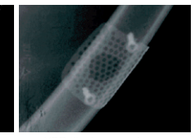

VBR titanium membrane x ray covering the defect

RESULTS

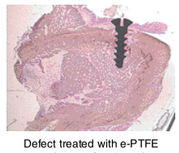

Defect treated with e-PTFE membrane after 8 weeks

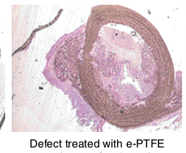

Defect treated with e-PTFE membrane after 8 weeks

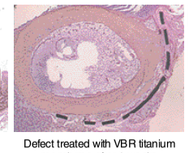

Defect treated with VBR titanium membrane after 8 weeks

New bone also inside the VBR titanium membrane holes after 8 weeks

CONCLUSIONS

- **All the defects of both groups were completely filled by mature, lamellar bone.**
- **No inflammatory cells infiltrate was present. No multinucleated giant cells were present.**
- **Newly formed bone was in close, direct contact with both membranes and no gaps were present. Both membranes adhered closely to the bone defects.**
- **The e-PTFE membrane appeared to be compressed, in a few areas, by the overlying soft tissues.**
- **The VBR membrane did not appear compressed in any areas.**
- **No differences were found in the quantity of the bone regeneration using these two types of membranes and both membranes have shown a high degree of biocompatibility, and did not induce any untoward effects.**

CLINICAL CASE 1

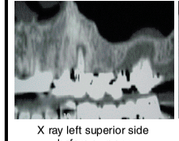

X ray left superior side before surgery

X ray left superior side before surgery

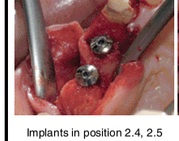

Implants in position 2.4, 2.5

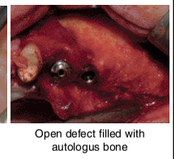

Open defect filled with autologus bone



VBR titanium telescopic membrane

VBR titanium telescopic membrane placed and fixed with four screws

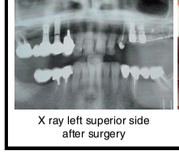

X ray left superior side after surgery

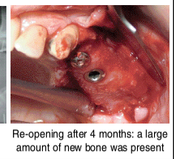

Re-opening after 4 months: a large amount of new bone was present

CLINICAL CASE 2

X- ray before surgery

Implants in position 2.4, 2.5, 2.6 and bone defects

Open defect filled with autologus bone

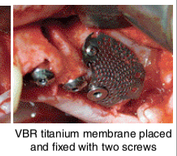

VBR titanium membrane placed and fixed with two screws

Re-opening after 4 months: a large amount of new bone was present

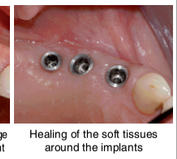

Healing of the soft tissues around the implants

X- ray control after surgery

P F M restoration

CLINICAL CASE 3

X- ray before surgery



X- ray after surgery

View of the inferior left side before surgery

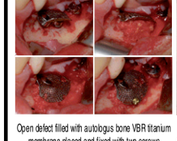

Open defect filled with autobogus bone VBR titanium membrane placed and fixed with two screws

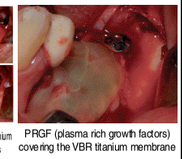

PRGF (plasma rich growth factors) covering the VBR titanium membrane

Healing of the soft tissues 8,15,30 days after surgery

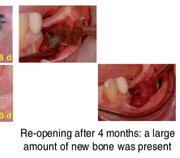

Re-opening after 4 months: a large amount of new bone was present

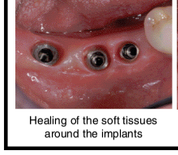

Healing of the soft tissues around the implants

PFM restoration