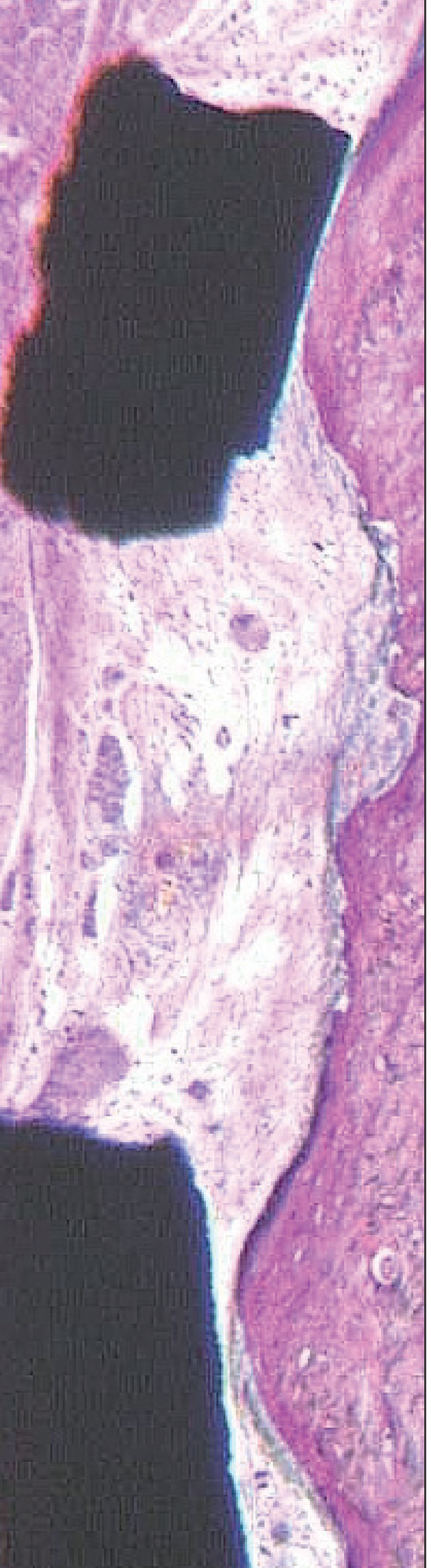

Riference **OP-BI0702001P1**

Publication date and location

February 15-17, 2007
Venice, Italy, Lido Congress Center

Event

5th World Congress of Osseointegration
Venice, Italy 15-17 February 2007

Headline scientific research

Bone Regeneration in femur defects in rabbits treated with a e-PTFE and a VBR titanium membrane

Authors

Lorenzo Ravera*, Antonio Scarano, Giovanna Iezzi**, Fabrizio Morelli*, Adriano Piattelli****

(*Private Practice, Torino, Italy, **Dental School, University of Chieti Pescara, Italy)

Index

ORALPLANT SUISSE SA
Division Implantology
Via Penate 16
CH-6850 Mendrisio

T +41 (0) 91 971 54 00
info@oralplant.ch

www.oralplant.com

Bone regeneration in femur defects in rabbits treated with a e-PTFE and a VBR titanium membrane

Lorenzo Ravera *, Antonio Scarano**, Giovanna Iezzi **, Fabrizio Morelli *, Adriano Piattelli**
(* Private Practice, Torino, Italy; ** Dental School, University of Chieti-Pescara, Italy)

INTRODUCTION

The need to insert dental implants with a guided prosthetic axis in patients with atrophy of the jaw-bone, has determined the use of numerous techniques of GUIDED BONE REGENERATION or AUGMENT: GBR/GBA (1,2,3)
The guided bone regeneration is based on the use of a membrane that, acting as a mechanical semi-waterproof barrier, excludes the connective and epithelial cells from the surgical repair and, at the same time, favours the osteo-promoting cells invasion (4)
The fundamental conditions to obtain the bone regeneration are:
maximum contact surface between the surrounding bone and the coagulum (5,6)
maximum coagulum stability (space making effect)
maximum overlying soft tissues respect
In bone defects with low space making capacity (open defects) the membrane, as well as creating a protective and semi-waterproof compartment for the coagulum, keeps the space (space making effect) favouring the osteo-genesis process (7)

AIM

The aim of this work was an histological study of the bone healing of femoral defects in rabbits treated with an e-PTFE titanium reinforced membrane (W. L. Gore & Associates, Flagstaff, AZ, USA) and a new titanium membrane VBR (Valve Bone Regeneration, Oralplant, Cordenons, Italy) and their space making capacity.

MATERIAL AND METHODS

- **Twelve New Zealand rabbits, weighing about 2,5 Kg, were used.**
- **One defect (6mm x 6mm) was created in each femur.**
- **Twelve defects were covered with e-PTFE membranes (control defects)**
- **Twelve defects were covered with VBR titanium membranes (test defects).**
- **The rabbits were killed after 8 weeks and the block sections, containing the bone defects, were retrieved.**
- **A total of 24 defects were retrieved and the specimens were processed to obtain thin ground sections. (8)**

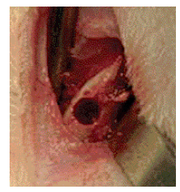
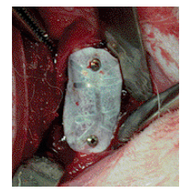
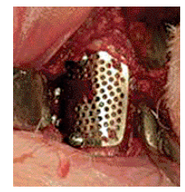

SURGICAL PROCEDURE

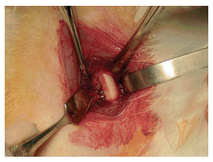
View of the anterior-superior femur surface

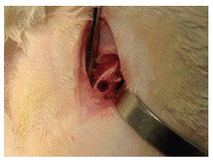
Bone defect

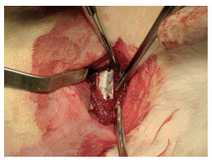
e-PTFE membrane placed and fixed with two screws

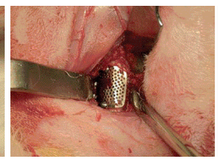
VBR titanium membrane placed and fixed with two screws

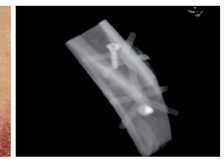
e-PTFE membrane x ray covering the defect

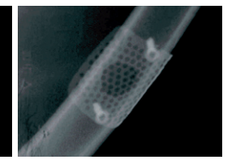
VBR titanium membrane x ray covering the defect

RESULTS

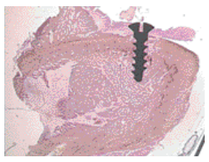
Defect treated with e-PTFE membrane after 8 weeks

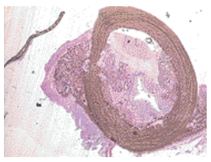
Defect treated with e-PTFE membrane after 8 weeks

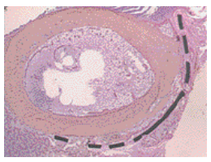
Defect treated with VBR titanium membrane after 8 weeks

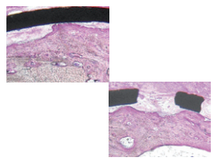
New bone also inside the VBR titanium membrane holes after 8 weeks

CONCLUSIONS

- **All the defects of both groups were completely filled by mature, lamel lar bone.**
- **No inflammatory cells infiltrate was present. No multi-nucleated giant cells were present.**
- **Newly formed bone was in close, direct contact with both membranes and no gaps were present. Both membranes adhered closely to the bone defects.**
- **The e-PTFE membrane appeared to be compressed, in a few areas, by the overlying soft tissues.**
- **The VBR membrane did not appear compressed in any areas.**
- **No differences were found in the quantity of the bone regeneration using these two types of membranes and both membranes have shown a high degree of biocompatibility, and did not induce any unto ward effects. (9,10,11,12,13)**

CLINICAL CASE 1

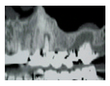
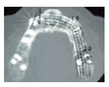
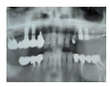
X ray left superior side before and after surgery

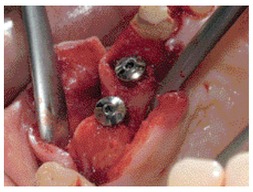
Implants in position 2.4, 2.5


VBR titanium telescopic membrane

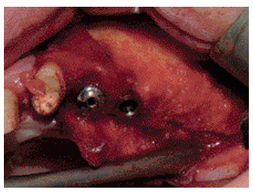
Open defect filled with autologus bone

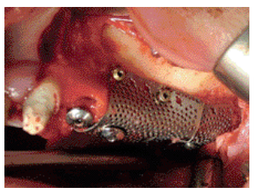
VBR titanium telescopic membrane placed and fixed with four screws

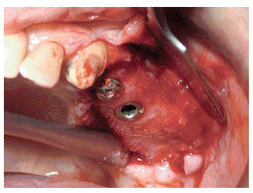
Re-opening after 4 months: a large amount of new bone was present

CLINICAL CASE 2

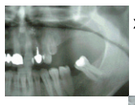
X- ray before surgery


X- ray control after surgery

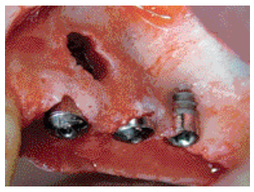
Implants in position 2.4, 2.5, 2.6 and bone defects

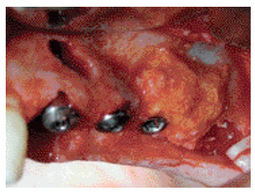
Open defect filled with autologus bone

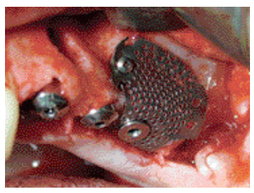
VBR titanium membrane placed and fixed with two screws

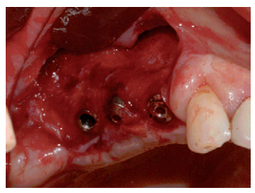
Re-opening after 4 months: a large amount of new bone was present

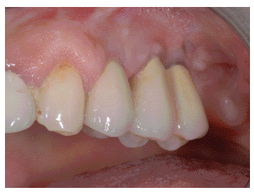
P F M

BIBLIOGRAPHY

1. Hurley AL, Stinchfield FE, Bassett CAL,Lyon WH.The role of soft tissues in osteogenesis (abstract). J Bone Joint Surg 1959;41A:1243.
2. Dahlin C. Sennerby L, Leklom U et al. Generation of new bone around titanium implants using a membrane technique: an experimental study in rabbits. Int.Oral Maxillofac Implant 1989;4:19-25.
3. Dahlin C,Linde A,Gottlow J,Nyman S.Healing of bone defects by guided bone regeneration. Plast Reconstr Surg 1988;81:672-676.
4. Jovannovic SA,Schenk RK,Orsini M et al.Supracrestal bone formation around dental implants: an experimental dog study. Int J Oral Maxillofac Impl 1995;10 :23-31.
5. Weigel PH, Fuller GM, LeBoeuf RD.A model for the role of hyaluronic acid and fibrin in the early events during the inflammatory response and wound healing. J Theor Biol 1986;119:219-34.
6. Bostrom MPG. Expression of bone morphogenetic proteins in fracture healing.Clin Orthop 1998;355:S116-S123.
7. Schenk RK,Buser D,Hardwick WR et al.Healing pattern of bone regeneration in membrane-protected defects: a histologic study in the canine mandible. Int J Oral Maxillofac Impl 1994;9:13-29.
8. Piattelli A, Scarano A, Quaranta M.High-precision,semi-automated, cost-effective system for producing thin sections of oral tissues containing dental implants. Biomaterials 1997;18:577-579.
9. Van Steenberghe D,Johansson C,Quirynen M,Molly L, Albrektsson T, Naert I. Bone augmentation by means of a stiff occlusive titanium barrier.A study in rabbits and humans. Clinical Oral Implants Research 2003;14:63-71.
10. Schmid J, Hämmerle CHF, Olah AJ. Lang NP. Membrane permeability is unnecessary for guided generation of new bone. An experimental study in the rabbit. Clinical Oral Implants Research 1994;5:125-130.
11. Lundgren D, Lundgren AK, Sennerby L, Nyman S. Augmentation of intramembranous bone beyond the skeletal envelope using an occlusive titanium barrier. An experimental study in the rabbit. Clinical Oral Implants Research 1995;6:67-72.
12. Lundgren AK,Lundgren D,Taylor A.Influence of barrier occlusiveness on guided bone augmentation. An experimental study in the rat. Clinical Oral Implants Research 1998;9:251-260.
13. Chierico A, Valentini R, Majzoub Z, Piattelli A, Scarano A, Okun L,Cordioli G. Electrically charged GTAM membranes stimulate osteogenesis in rabbit calvarial defects. Clinical Oral Implants Research 1999;10: 415-424.